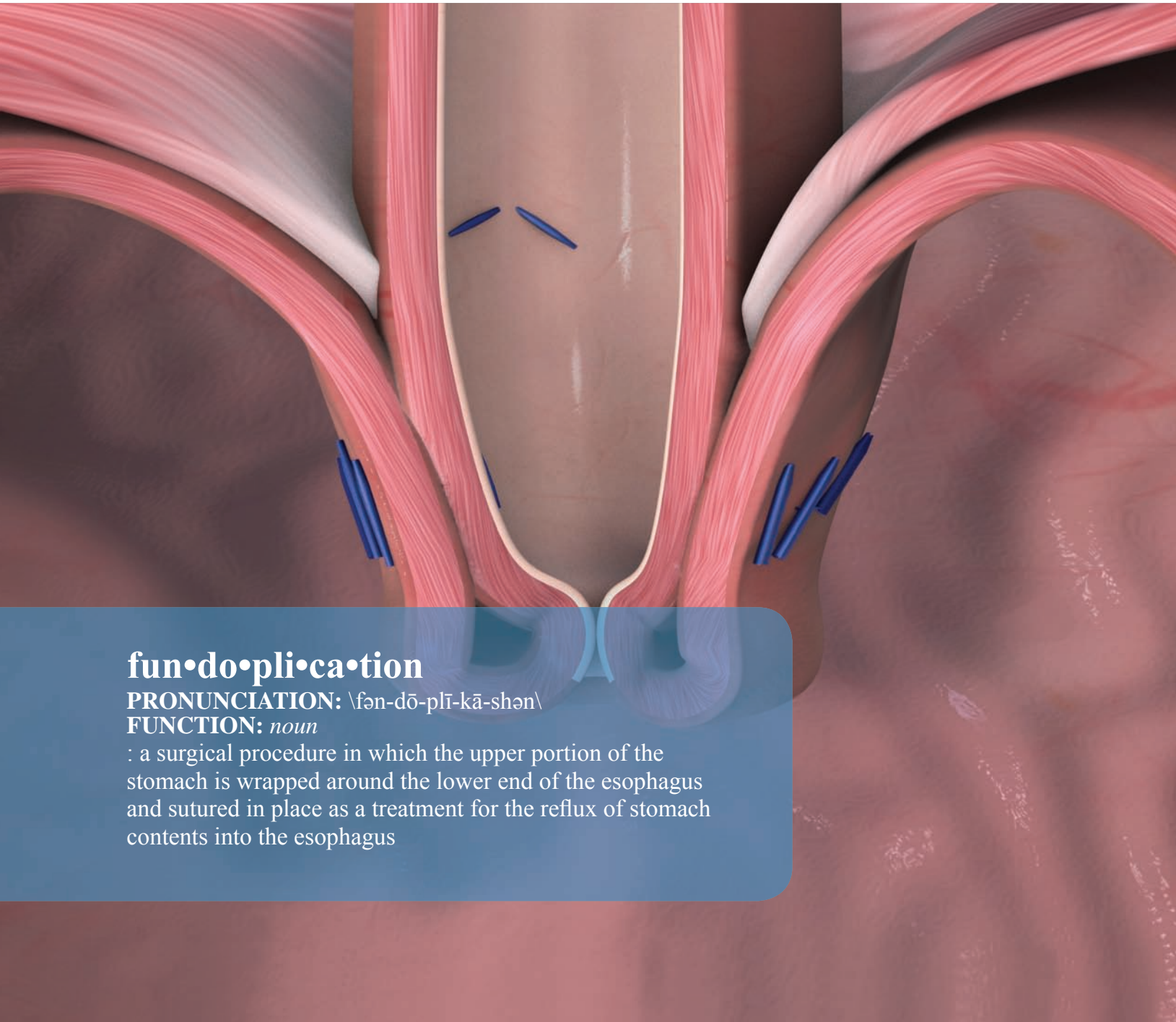




TIF

Transoral Incisionless
Fundoplication



fun•do•pli•ca•tion

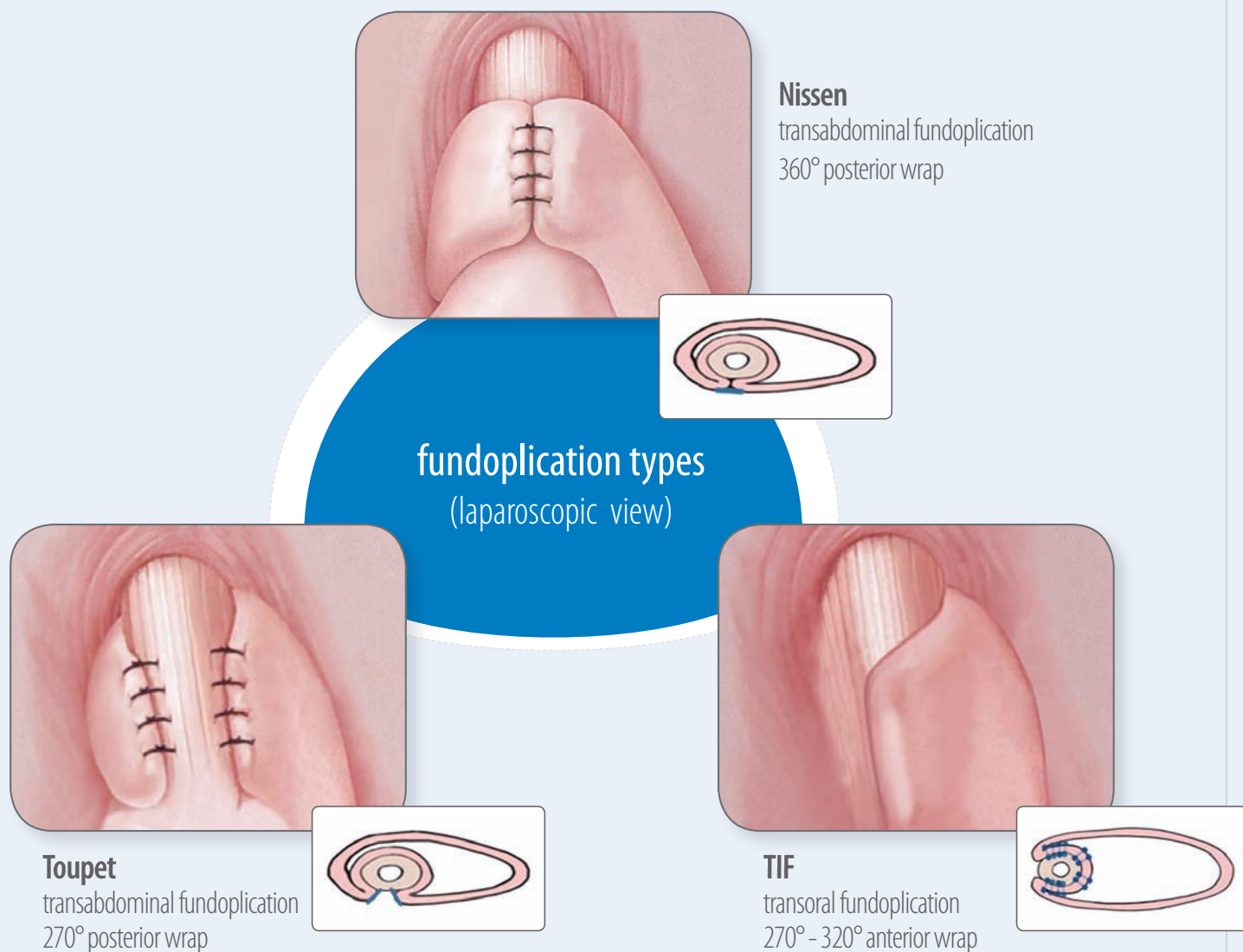
PRONUNCIATION: \ˈfən-dō-plī-kā-shən\

FUNCTION: *noun*

: a surgical procedure in which the upper portion of the stomach is wrapped around the lower end of the esophagus and sutured in place as a treatment for the reflux of stomach contents into the esophagus

A less invasive approach to fundoplication

Fundoplication procedures have been used to effectively treat patients with GERD for over 50 years. TIF is a fundoplication procedure performed through the mouth, rather than through abdominal incisions.



“The transoral incisionless fundoplication (TIF)... adheres to the fundamental surgical principles which have guided surgical care for GERD for more than 50 years; specifically the creation of a full thickness gastric fundoplication in support of the lower esophageal sphincter.”

ASGS (American Society of General Surgeons) Board of Trustees
in a 2009 position statement in support of the TIF procedure

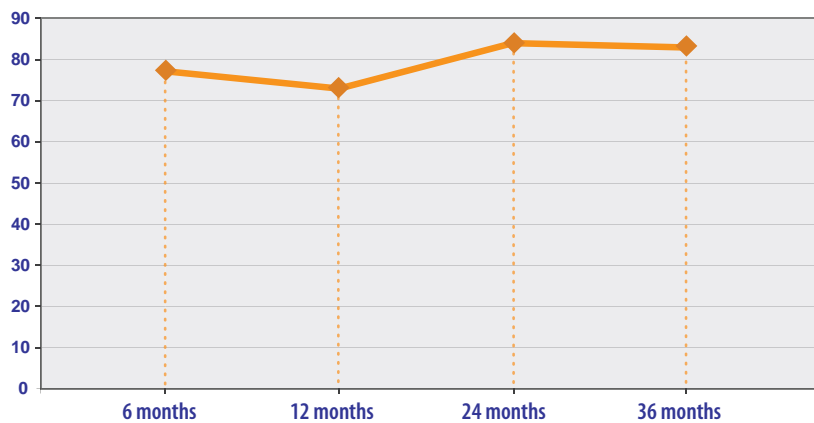
Clinical Results

TIF performs similarly to the Nissen and Toupet procedures in standard measures of clinical efficacy

	TIF	Toupet	Nissen
GERD-HRQL improved by \geq 50%	70-92%	65-95%	61-97%
Off daily PPIs	72-97%	65-92%	79-99%
Esophagitis reduced	67-90%	82-89%	86-95%
Hiatal hernia reduced	60-89%	90-95%	87-99%

TIF delivers sustainable results

% of patients with GERD-HRQL scores improved by \geq 50% vs. baseline off PPIs

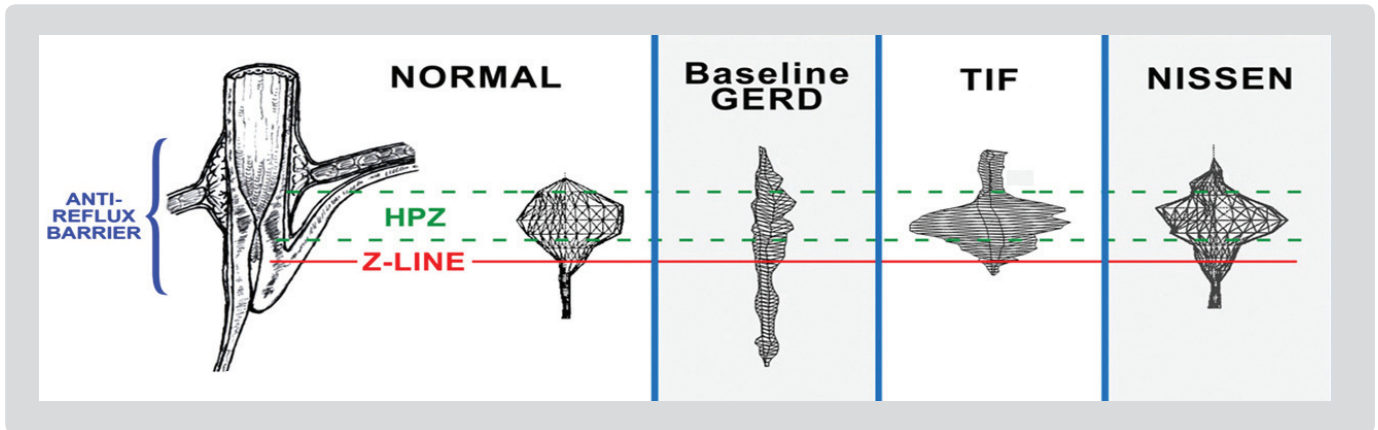


TIF reduces the risk of complications associated with more invasive fundoplication procedures

	TIF	Nissen
Intraoperative complications:		
• Perforations	0.1%	1-4%
Postoperative complications:		
• Abdominal pain	9-14%	10-40%
• Dysphagia	0-11%	44-90%
• Diarrhea	0-5%	18-20%
• Gas bloat	3-59%	10-82%
• Nausea	2-11%	8-21%
Long-term complications:		
• Chronic dysphagia	0%	2-6%
• Gas bloat syndrome	0%	9-62%
• Reoperation	0%	4-8%
Mortality	0%	0.5-3%

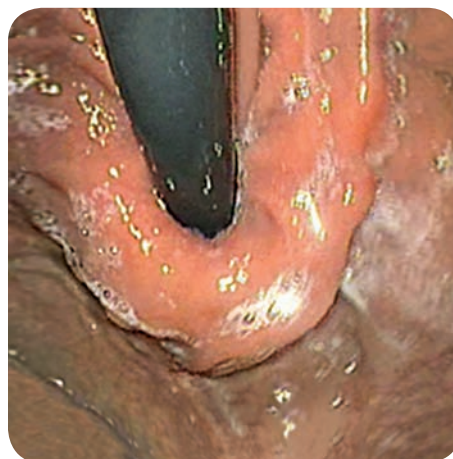“This is incisionless surgery with REAL results for a lot of people, and we can do it right now.”

Mark Gibbs, MD
Little Rock, AR

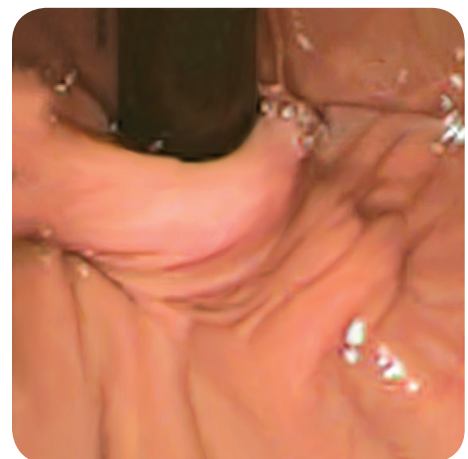

TIF valves have a vector volume (3-D manometry) profile similar to those of normal and Nissen valves. This change in pressure and length of the high-pressure zone (HPZ) is believed to result in antireflux barrier competence.

Viewed endoscopically, transoral and laparoscopic fundoplication valves are very similar.



TIF

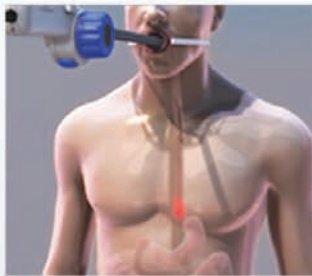


Laparoscopic Fundoplication

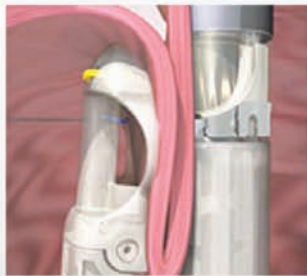TIF elongates the esophagus and creates a 270–320° esophagogastric valve incorporating and tightening the phrenoesophageal membrane. TIF is based on and closely emulates the surgical principles of more invasive fundoplication techniques.

Objectives of Fundoplication

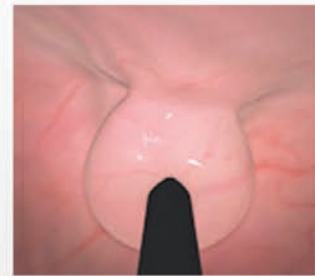
Requirement	TIF	Toupet	Nissen
Tightens greater curve side of cardia (collar-sling) to lesser curve side (clasp)	✓	✓	✓
Submerges distal esophagus into proximal stomach	✓	✓	✓
Recreates the Angle of His	✓	✓	✓
Creates an evident valve the length of the fundoplication	✓	✓	✓
Enveloped esophagus compresses with increasing intragastric pressure	✓	✓	✓
Restores intraabdominal esophageal length	✓	✓	✓
Tightens phrenoesophageal membrane	✓	✓	✓
Reduces hiatal hernia <2cm	✓	✓	✓
Repairs hiatal hernia >2 cm and allows closure of crura		✓	✓



Step 1: The EsophyX device is inserted into the esophagus through the mouth and is positioned at the junction of the stomach and esophagus. Hiatal hernia is reduced by engaging suction and positioning the esophagus below the diaphragm.



Step 2: A full thickness tissue fold at the gastroesophageal junction is retracted, wrapped and anchored using fasteners equivalent to 3.0 sutures, which are delivered across the tissue to complete the plication.



Step 3: The valve is extended and multiple fasteners (14-20) are delivered with only a single device insertion. TIF reconstructs the primary components of the antireflux barrier, creating a tight 3-5 cm valve enveloping the distal esophagus below the diaphragm.

By objective measures, the TIF procedure achieves what a fundoplication is expected to achieve – improvement in LES parameters and reduction in acid exposure. 🎯

Reginald Bell, MD
Englewood, CO

“The TIF procedure allows us to do a surgical correction without the same rate of risk, and with faster recovery than what is associated with more invasive laparoscopic or open procedures.”

Mike Thomson, MD
Sheffield, UK



TIF References

1. Barnes WE, Hoddinott KM, Mundy S, Williams M Transoral incisionless fundoplication improves reflux symptoms in long-time PPI users with therapy-resistant symptoms: a multicenter retrospective study with 120 patients. *Surg Endosc* (in preparation)
2. Bell RCW, Freeman K Clinical outcomes of transoral esophago-gastric fundoplication for the treatment of gastroesophageal reflux disease. *Surg Endosc* (in preparation)
3. Cadière GB, Buset M, Muls V, Rajan A, Rosch T, Eckardt AJ, Weerts J, Bastens B, Costamagna G, Marchese M, Louis H, Mana F, Sermon F, Gawlicka AK, Daniel MA, Deviere J (2008). Antireflux transoral incisionless fundoplication using EsophyX: 12-month results of a prospective multicenter study. *World J Surg* 32:1676-88
4. Cadière GB, Van Sante N, Graves JE, Gawlicka AK, Rajan A (2009). Two-year results of a feasibility study on antireflux transoral incisionless fundoplication (TIF) using EsophyX. *Surg Endosc* 23:957-964
5. Muls V, Marchese M, Eckardt AJ, Cadière GB, Buset M, Rajan A, Weerts J, Bastens B, Deviere J, Louis H, Mana F, Gawlicka AK, Daniel MA, Costamagna G Antireflux transoral incisionless fundoplication using EsophyX: three-year results of a prospective multicenter study. *GI Endosc* (in preparation)
6. Testoni PA, Corsetti M, Di Pietro S, Castellaneta AG, Vailati C, Masci E, Passaretti S (2010). Effect of transoral incisionless fundoplication on symptoms, PPI use, and pH-impedance refluxes of GERD patients. *World J Surg* (ePub ahead of print, 21 January 2010)

Toupet References

1. Catarci M, Gentileschi P, Papi C, Carrara A, Marrese R, Gaspari AL, Grassi GB (2004). Evidence-based appraisal of antireflux fundoplication. *Ann Surg* 239:325-37
2. Guerin E, Betroune K, Closset J, Mehdi A, Lefebvre JC, Houben JJ, Gelin M, Vaneukem P, El Nakadi I (2007). Nissen versus Toupet fundoplication: results of a randomized and multicenter trial. *Surg Endosc* 21:1985-90
3. Horvath KD, Jobe BA, Herron DM, Swanstrom LL (1999). Laparoscopic Toupet fundoplication is an inadequate procedure for patients with severe reflux disease. *J Gastrointest Surg* 3:583-91
4. Jobe BA, Wallace J, Hansen PD, Swanstrom LL (1997). Evaluation of laparoscopic Toupet fundoplication as a primary repair for all patients with medically resistant gastroesophageal reflux. *Surg Endosc* 11:1080-3
5. Sgromo B, Irvine LA, Cuschieri A, Shimi SM (2008). Long-term comparative outcome between laparoscopic total Nissen and Toupet fundoplication: Symptomatic relief, patient satisfaction and quality of life. *Surg Endosc* 22:1048-53

Nissen References

1. Funch-Jensen P, Bendixen A, Iversen MG, Kehlet H (2008). Complications and frequency of redo antireflux surgery in Denmark: a nationwide study, 1997-2005. *Surg Endosc*
2. Hahnloser D, Schumacher M, Cavin R, Cosendey B, Petropoulos P (2002). Risk factors for complications of laparoscopic Nissen fundoplication. *Surg Endosc* 16:43-7
3. Hunter JG, Swanstrom L, Waring JP (1996). Dysphagia after laparoscopic antireflux surgery. The impact of operative technique. *Ann Surg* 224:51-7
4. Hunter JG, Trus TL, Branum GD, Waring JP, Wood WC (1996). A physiologic approach to laparoscopic fundoplication for gastroesophageal reflux disease. *Ann Surg* 223:673-685
5. Lind T (2000). Changing surgical principles for gastro-oesophageal reflux disease--is laparoscopic fundoplication justified in the light of surgical complications? *Eur J Surg Suppl*:31-3
6. Lundell L (2004). Complications after anti-reflux surgery. *Best Pract Res Clin Gastroenterol* 18:935-945
7. Lundell L, Abrahamsson H, Ruth M, Rydberg L, Lonroth H, Olbe L (1996). Long-term results of a prospective randomized comparison of total fundic wrap (Nissen-Rossetti) or semifundoplication (Toupet) for gastro-oesophageal reflux. *Br J Surg* 83:830-5
8. Lundell L, Attwood S, Eil C, Fiocca R, Galmiche JP, Hatlebakk J, Lind T, Junghard O (2008). Comparing laparoscopic antireflux surgery with esomeprazole in the management of patients with chronic gastro-oesophageal reflux disease: a 3-year interim analysis of the LOTUS trial. *Gut* 57:1207-13
9. Lundell L, Miettinen P, Myrvold HE, Hatlebakk JG, Wallin L, Malm A, Sutherland I, Walan A (2007). Seven-year follow-up of a randomized clinical trial comparing proton-pump inhibition with surgical therapy for reflux oesophagitis. *Br J Surg* 94:198-203
10. Pearson FG (1997). Complications and pitfalls: Belsey and Collis-Belsey antireflux repairs. *Chest Surg Clin N Am* 7:513-32
11. Urschel JD (1993). Complications of antireflux surgery. *Am J Surg* 166:68-70
12. Waring JP (1999). Management of postfundoplication complications. *Semin Gastrointest Dis* 10:121-9

8210 154th NE
Redmond, WA 98052
Tel: 425.307.9200 Fax: 425.307.9201

555 Twin Dolphin Drive, Ste. 620
Redwood City, CA 94065
Tel: 650.226.2200 Fax: 650.226.2201

 **EndoGastric Solutions®**
www.endogastricsolutions.com